

## BRIEF REPORT

# Use of the Venture Wire-Control Catheter for Accessing Side Branches During Provisional Stenting: An Option for Bifurcations With an Unfavorable Anatomy

Soledad Ojeda, Manuel Pan, Francisco Mazuelos, Miguel Romero, José Segura, Djordje Pavlovic, Manuel Crespín, and José Suárez de Lezo

Servicio de Cardiología, Hospital Universitario Reina Sofía, Córdoba, Spain

We report our experience with the Venture wire-control catheter in 20 patients with bifurcation lesions in which it was impossible to access the side branch using conventional techniques. This device was always used as a last resort and was employed during different stages in the treatment of the bifurcation lesions (i.e. initially, after stenting of the main vessel, or both). In 17 patients (85%), use of the Venture catheter resulted in the success of the procedure. Only one complication associated with a monorail catheter was recorded. It was resolved successfully. One patient died from heart failure 10 days after the procedure and 2 patients, in whom it was impossible to access the side branch, had non-Q-wave myocardial infarctions. In conclusion, the Venture catheter was effective and safe, and enabled the side branches of complex bifurcation lesions to be accessed.

**Key words:** *Coronary heart disease. Bifurcation lesions. New devices.*

## Utilidad del catéter Venture para acceder al ramo lateral en la técnica de *stent* provisional: una alternativa para bifurcaciones con anatomías desfavorables

Describimos nuestra experiencia con el catéter Venture en 20 pacientes con lesiones en bifurcación en los que fue imposible cruzar al ramo lateral con la tecnología habitual. Este dispositivo se utilizó siempre como último recurso y en diferentes etapas del tratamiento de la bifurcación (basal, post-*stent* en el vaso principal o en ambas). En 17 pacientes (85%), el catéter Venture condujo al éxito del procedimiento. Sólo se registró una complicación relacionada con un catéter monorraíl, la cual se resolvió exitosamente. Un paciente murió por insuficiencia cardíaca 10 días después del procedimiento y 2 pacientes, en los que fue imposible acceder al ramo lateral, sufrieron un infarto no-Q. En conclusión, el catéter Venture es útil y seguro, y permite acceder al ramo lateral en lesiones bifurcadas complejas.

**Palabras clave:** *Enfermedad coronaria. Lesiones bifurcadas. Nuevos dispositivos.*

## INTRODUCTION

Despite technological progress, bifurcation lesions continue to present technical difficulties that are accentuated in certain anatomical conditions, such as extreme vessel tortuosity, extreme angulation of the origin of the side branch (SB) in relation to the main vessel (MV), or severe stenosis in both vessels, since they can prevent access and, as a result, treatment of the SB.<sup>1</sup> In these situations, a steerable deflectable-tip device may have a relevant role when dealing

with this subgroup of lesions. We describe our experience with the Venture wire-control catheter (St. Jude Medical, Minnesota, United States) to cross the side branch in complex bifurcation lesions with an unfavorable anatomy in which conventional techniques had failed.

## METHODS

Between April 2006 and September 2009, 553 patients with bifurcated lesions were treated percutaneously. We examined 20 (4%) patients in whom the Venture catheter was used when it was impossible to access the SB using conventional techniques and methods. Using a chronometer, we recorded the time taken to access the SB, and noted the number of guidewires used. The procedures were performed by an expert operator following a previously described stepwise strategy.<sup>2</sup>

Correspondence: Dra. S. Ojeda.  
Servicio de Cardiología. Hospital Universitario Reina Sofía.  
Avda. Menéndez Pidal, s/n. 14004 Córdoba. Spain.  
E-mail: soledad.ojeda18@gmail.com

Received September 16, 2009.  
Accepted for publication January 13, 2010.

We used the CardiOp-B system (Paeion, Rosh Ha'ayin, Israel) to measure the bifurcation angles: the take-off angle (between the proximal MV and the SB) and the carina angle (between the distal MV and the SB).<sup>3</sup>

### Device and Procedure

The Venture catheter supports a 6 Fr guidewire catheter and is available in coaxial or monorail versions. The interior light makes it possible to use any coronary guidewire. It has a radiopaque 8-mm distal tip that can be deflected up to 90° with a clockwise torque shaft in the proximal area of the catheter. To avoid injury, the Venture catheter is advanced to the lesion in its straight configuration along a guidewire. Having reached the target, the tip is deflected to the desired angle. The fact that it can be deflected, together with the possibility of rotating the catheter tip in a circumferential plane, makes it easier to steer the guidewire and access the lesion, while providing excellent support. Once it has passed beyond the guidewire, it is turned anticlockwise to straighten the tip and thus can be withdrawn.<sup>4</sup>

We analyzed the success and complication rates of the Venture catheter, its influence on the number of guidewires used, and the duration of the procedure. Procedural was defined as successful when the guidewire was passed through the true lumen of the SB allowing thus the further treatment of it with no complications. Serial determination of markers of myocardial damage (troponin, creatine phosphokinase [CPK], and the MB fraction of CPK) was performed.

### Statistical Analysis

Quantitative variables are expressed as medians and 25-75 percentiles, and qualitative variables as percentages. Comparisons were made using a nonparametric test (Wilcoxon).

## RESULTS

### Baseline and Procedural Data

Table 1 shows clinical, angiographic and procedural data. At least, 2 guidewires were used before resorting to the Venture catheter (median, 3; 25-75 percentile, 2-3), whereas only 1 was needed with the Venture in the patients treated successfully (median, 1; percentile 25-75, 1-1) ( $P<.01$ ) (Table 2). The median SB access time using conventional techniques was 16 minutes (25-75 percentile, 11.7-20.5), whereas this was reduced to 2.5 minutes (25-75 percentile, 1.8-3) using the Venture catheter ( $P<.01$ ).

**TABLE 1. Clinical, Angiographic, and Procedural Data**

<b>Clinical</b>	
Age (y)	71.5 (53-79.5)
Men	15 (75%)
Diabetes	9 (45%)
Hypertension	13 (65%)
Hypercholesterolemia	9 (45%)
Smoker	5 (25%)
Unstable angina	12 (60%)
<b>Angiographic</b>	
Bifurcation treated	
LAD-1, diagonal	10 (50%)
PD-PLA	4 (20%)
Cx-OM	4 (20%)
Distal LM	2 (10%)
Type of bifurcation	
1.1.1	14 (70%)
1.0.1	6 (30%)
Baseline SB stenosis	71 (61.2-81.2)
Calcification at SB origin	15 (75%)
<b>Procedure</b>	
Drug-eluting stent	20 (100%)
TIMI flow in SB poststent MV	
0	4 (20%)
I	2 (10%)
II	6 (30%)
III	8 (40%)
Post stenting CPK (U/L)	105.5 (75.2-260.2)
Post stenting troponin (U/L)	0.7 (0.4-1.1)

Abbreviations: LAD, left anterior descending artery; Cx, circumflex artery; LM, left main; MV, main vessel; OM, obtuse marginal; PD, posterior descending artery; PLA, posterolateral artery; SB, side branch.

All data are expressed as n (%) or median (25-75 percentiles).

Access times were reduced with experience in using the catheter, and this also influenced the success rate, since the failures occurred during the initial stages of the learning curve. In 10 (50%) patients, the catheter was initially used to access the SB; in 7 (35%) to cross the jailed side branch; and in 3 (15%), it was used in both stages.

### Procedural Success

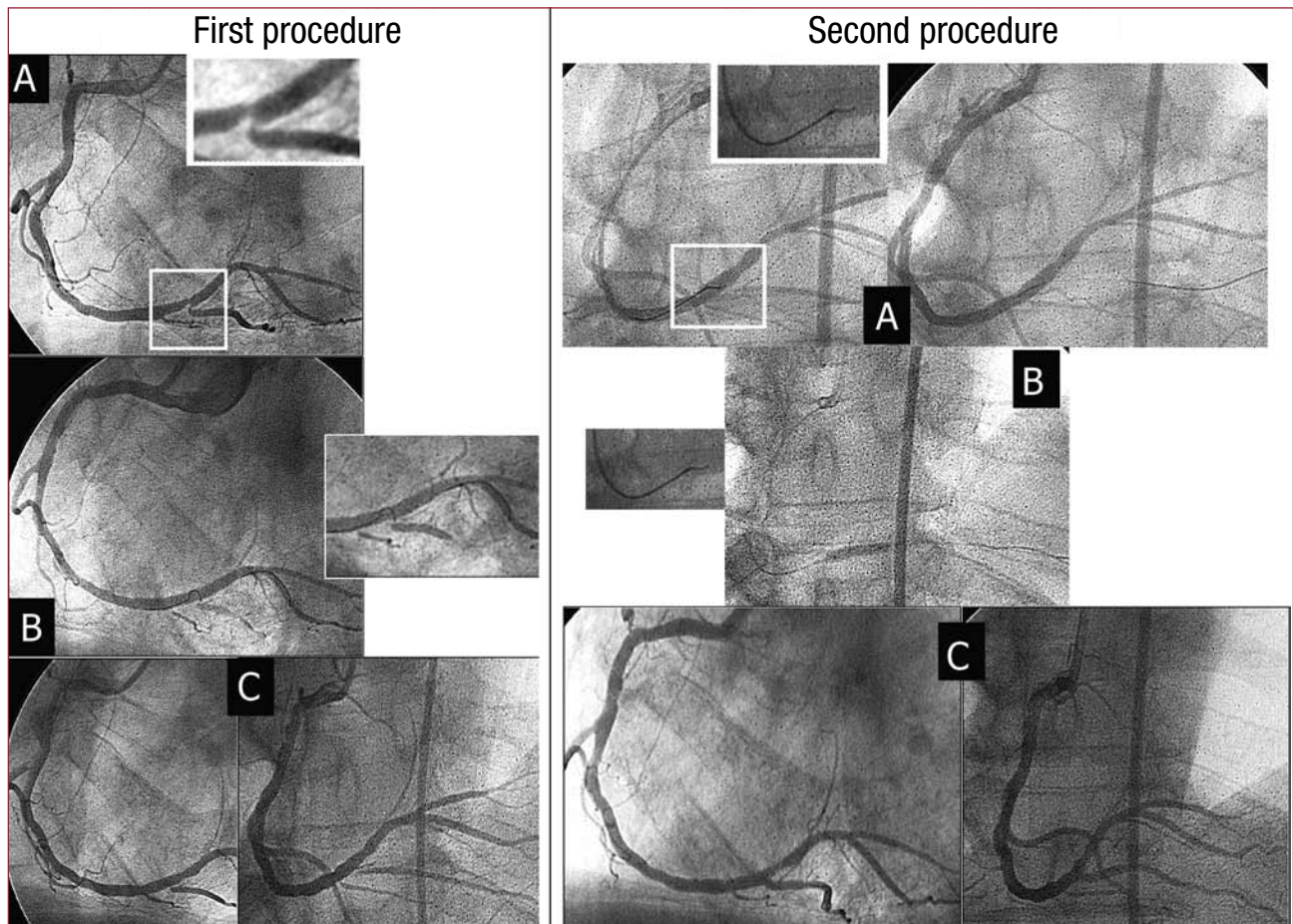
In 17 patients (85%), the guidewire was successfully used to access the SB and treat the bifurcation (Table 2). Figure 1 shows the first procedure in which this catheter was used. Only one complication occurred (patient 12) which was associated with a monorail catheter. This involved a patient with a severe lesion in the distal left main coronary artery. There was a severe, calcified and very angulated lesion at the origin of the circumflex artery, which required the use of the Venture catheter, following failure with various guidewires. Once the lesion was crossed, a guidewire was left as a marker and a stent implanted in the left main coronary artery, oriented toward the descending anterior artery covering the circumflex.

**TABLE 2. Anatomical and Procedural Characteristics of the Patients and Immediate Outcomes**

Patient	Location	Take-off Angle	Carina Angle	Pre-VC Guidewires	Use of VC	Success
1	Distal RC	87°	103°	2 Whisper, <sup>a</sup> 1 BMW <sup>a</sup>	Post- stent	Yes
2	LAD-D1	104°	100°	2 Whisper, 1 BMW	Post- stent	No
3	LAD-D1	149°	54°	2 Pilot 50, <sup>a</sup> 1 BMW	Baseline	Yes
4	LAD-D1	126°	127°	2 Whisper, 2 Pilot 50, 2 Pilot 150 <sup>a</sup>	Baseline	No
5	Distal RC	122°	72°	2 Pilot 50, 1 Whisper	Baseline and post- stent	Yes
6	LAD-D1	107°	71°	1 Whisper, 2 Pilot 50	Baseline	Yes
7	Cx-OM	99°	87°	1 Whisper extrasupport, <sup>a</sup> 1 Pilot 50	Baseline	Yes
8	Distal LM	102°	114°	2 Pilot 50	Post- stent	No
9	Cx-OM	117°	65°	1 50, 1 Whisper	Baseline	Yes
10	Distal RC	104°	99°	2 Pilot 50, 3 Whisper	Baseline	Yes
11	LAD-D1	127°	97°	2 Pilot 50, 1 Whisper	Baseline	Yes
12	Distal LM	68°	126°	2 BMW, 2 Whisper	Baseline and post- stent	Yes
13	LAD-D1	125°	47°	1 Whisper extrasupport, 1 Pilot 50	Post- stent	No
14	LAD-D1	83°	114°	1 Whisper extrasupport, 1 Pilot 150	Baseline and post- stent	Yes
15	LAD-D1	134°	58°	1 Pilot 50, 1 Whisper	Post- stent	Yes
16	Cx-OM	126°	86°	2 Pilot 50	Post- stent	Yes
17	LAD-D1	144°	59°	2 Pilot 50	Baseline	Yes
18	Distal RC	142°	47°	2 Pilot 50, 1 Whisper	Post- stent	Yes
19	LAD-D1	119°	74°	1 BMW, 1 Whisper	Baseline	Yes
20	Cx-OM	87°	53°	1 Pilot 50, 1 Whisper	Baseline	Yes

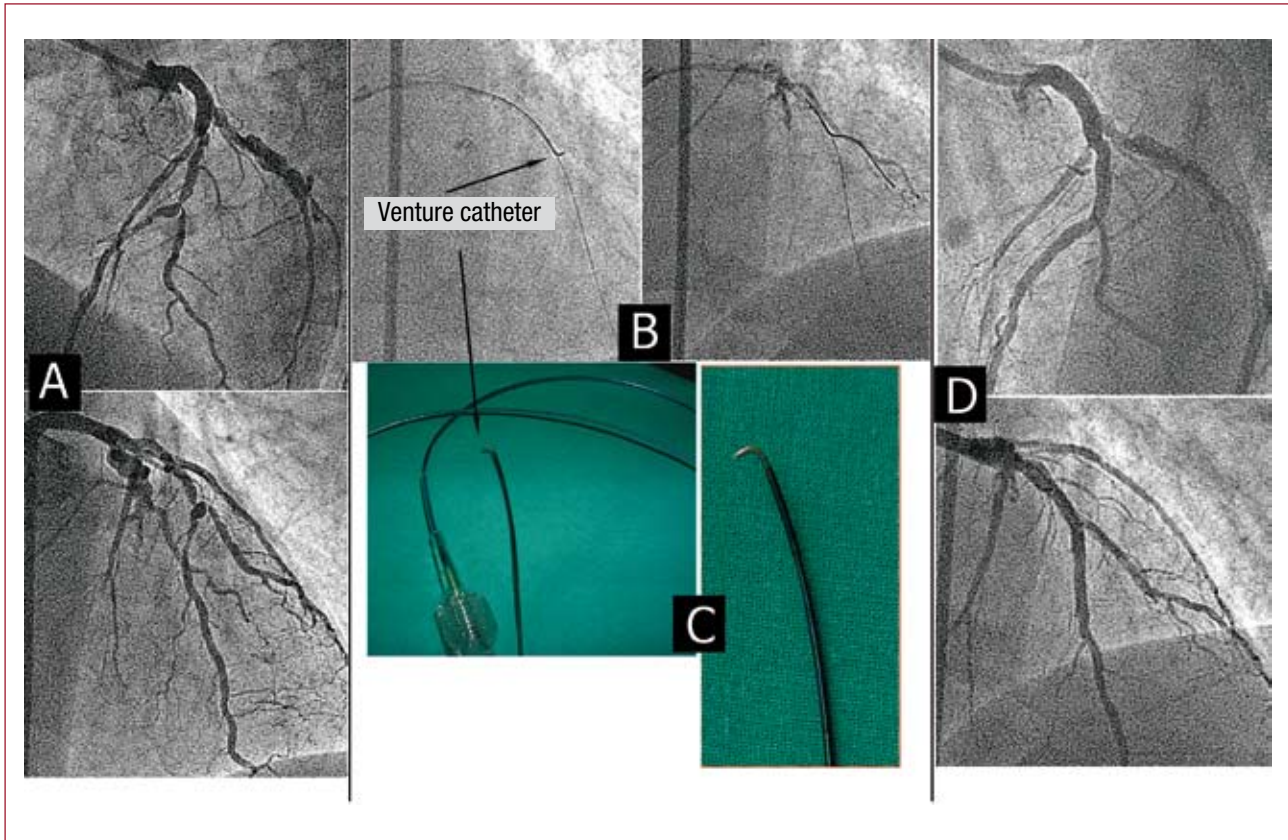
AD indicates left anterior descending artery; Cx, circumflex artery; OM, obtuse marginal; RC, right coronary artery; VC, Venture catheter.

<sup>a</sup>Abbott Vascular Devices, Redwood City, California, United States.



**Figure 1.** First procedure. A: severe lesion in the distal right coronary artery with a very angulated take-off of the posterior descending artery (PD). B: impossible to access the DP with a microcatheter and preformed guidewire. C: final result. Second procedure. A: Venture catheter. The deflectable tip allows the guidewire to be advanced. B: PD dilatation. C: final result.





**Figure 2.** A: critical lesion in the left anterior descending/first diagonal. B: Venture deflected and guidewire advanced. C: Venture catheter. D: final result.

For its subsequent dilatation, it was recrossed using the Venture monorail. When we attempted to withdraw the guidewire, it was partially torn, frayed, and wrapped around the catheter and the other coronary guidewires, making it impossible to extract it without removing the whole system, including the catheter. The procedure was finally completed successfully.

We did not observe any case of dissection or perforation, even though all patients had a severe lesion in the MV that left a very narrow lumen through which to direct the catheter. Figure 2 shows another example in which the Venture catheter played a key role in treating the bifurcation.

### Hospital Outcomes

The majority of the patients (17/20; 85%) were discharged without complications. One patient with multivessel disease and ventricular dysfunction died after the procedure due to heart failure. Two patients developed a non-Q myocardial infarction due to the impossibility to recross jailed and compromised side branch despite using the Venture catheter.

## DISCUSSION

### Difficulties of Provisional Stenting

Currently, provisional stenting or a simple stenting strategy is the standard treatment for bifurcated lesions.<sup>5</sup> Advancing a guidewire to the SB is a key maneuver for several reasons: it enables predilatation if required and, if it is occluded or dissected, it is useful as a marker of the true lumen. It also facilitates better intubation of the guidewire catheter when additional support is required. However, this can be difficult at times and we encountered problems in accessing the SB due to very severe lesions in both vessels or to an extreme angulation of the SB take-off. Furthermore, the stent in the MV may displace the carina and block the branch, which can complicate recrossing despite using a wide variety of coronary guidewires. Few studies describe the percentage of patients in whom it was impossible to access the SB. We previously reported a failure rate of 3%.<sup>6</sup> It is in this group that the Venture catheter plays a role.

Another point of interest is that 6 patients had a 1.0.1 bifurcation.<sup>7</sup> We think that this anatomy

provides certain technical advantages, since the absence of disease in the distal segment of the MV allows better tip rotation and deflection, which facilitates orienting the guidewire toward the SB.

### Previous Experience

Since McClure et al<sup>4</sup> described the use of this catheter in a series of patients with complex coronary lesions, several authors have corroborated the safety and efficacy of this device.<sup>8-11</sup> To date, this is the largest published series focused on the usefulness of the Venture catheter in bifurcation lesions, in which it was impossible to access the SB using conventional techniques. In these situations, the Venture catheter is the only tool that can steer the guidewire toward the lesion and that also provides additional support. Recently, Aranzulla et al<sup>11</sup> have described the use of this catheter as an option after standard guidewires had failed in 18 patients with complex lesions (7 bifurcations), with an overall success rate between 78% and 85% in bifurcated lesions, similar to the values communicated by our group.

In terms of safety, complications associated with the catheter have not been documented. Our group experienced only one complication, described above, with the monorail catheter. This may have been due to the fact that the lateral opening of the catheter, which is slightly sharp, partially cut and frayed the guidewire during repeated rotation of the catheter.

In conclusion, the Venture catheter has been proven safe and effective and its use leads to successful outcomes in the percutaneous treatment of complex bifurcated lesions that would have failed using conventional techniques.

### REFERENCES

1. Krone RJ, Shaw RE, Klein LW, Block PC, Anderson HV, Weintraub WS, et al. Evaluation of the American College of Cardiology/American Heart Association and the Society for Coronary Angiography and Interventions lesion classification system in the current "stent era" of coronary interventions (from the ACC-National Cardiovascular Data Registry). *Am J Cardiol.* 2003;92:389-94.
2. Pan M, Suárez de Lezo J, Medina A, Romero M, Segura J, Ramírez A, et al. A stepwise strategy for the stent treatment of bifurcated coronary lesions. *Catheter Cardiovasc Interv.* 2002;55:50-7.
3. Lansky A, Tuinenburg J, Costa M, Maeng M, Koning G, Popma J, et al. European Bifurcation Angiographic Sub-Committee. Quantitative angiographic methods for bifurcation lesions: A consensus statement from the European Bifurcation Club. *Catheter Cardiovasc Interv.* 2009;73:258-66.
4. McClure SJ, Wahr DW, Webb JG. Venture wire control catheter. *Catheter Cardiovasc Interv.* 2005;66:346-50.
5. Legrand V, Thomas M, Zelizko M, de Bruyne B, Reifart N, Steigen T, et al. Percutaneous coronary intervention of bifurcation lesions: state-of-the-art. Insights from the second meeting of the European Bifurcation Club. *EuroInterv.* 2007;3:44-9.
6. Pan M, Suárez de Lezo J, Medina A, Romero M, Delgado A, Segura J, et al. Drug-eluting stents for the treatment of bifurcation lesions: A randomized comparison between paclitaxel and sirolimus eluting stents. *Am Heart J.* 2007;153:15.e1-7.
7. Medina A, Suárez de Lezo J, Pan M. Una clasificación simple de las lesiones coronarias en bifurcación. *Rev Esp Cardiol.* 2006;59:183.
8. McNulty E, Cohen J, Chou T, Shunk K. A "grapple hook" technique using a deflectable tip catheter to facilitate complex proximal circumflex interventions. *Catheter Cardiovasc Interv.* 2006;67:46-8.
9. Routledge H, Lefevre T, Ohanessian A, Louvard Y, Dumas P, Morice MC. Use of a deflectable tip catheter to facilitate complex interventions beyond insertion of coronary bypass grafts: three case reports. *Catheter Cardiovasc Interv.* 2007;70:862-6.
10. Hussain F, Rajaram M. The Venture-balloon crush technique to treat a severely angulated bifurcation lesion via the radial approach—lessons learned. *Int J Cardiol.* 2007;120:e6-8.
11. Aranzulla TC, Sangiorgi GM, Bartorelli A, Cosgrave J, Corbett S, Fabbiochi F, et al. Use of the Venture<sup>TM</sup> wire control catheter to access complex coronary lesions: how to turn procedural failure into success. *EuroInterv.* 2008;4:277-84.